

A Pediatric Right Lower Quadrant Pain Case

Çiğdem Üner¹, Oğuzhan Tokur^{2*}, Sonay Aydın³, Fatma Dilek Gökharman²

¹Department of Radiology, Dr. Sami Ulus Training and Research Hospital, Ankara, Turkey, ²Department of Radiology, Ankara Training and Research Hospital, Ankara, Turkey, ³Department of Radiology, Faculty of Medicine, Erzincan Binali Yıldırım University, Erzincan, Turkey

SECTION 1 – Quiz

CASE

A 4-year-old male patient was admitted to the emergency department with right lower quadrant pain. On physical examination, there was tenderness and voluntary defense in the right lower quadrant. Rebound tenderness was not observed. Initially, the patient was sent for sonographic examination [Figure 1] and then to the abdominal radiography [Figure 2]. Images of the mentioned examinations are shown.

WHAT IS YOUR DIAGNOSIS?

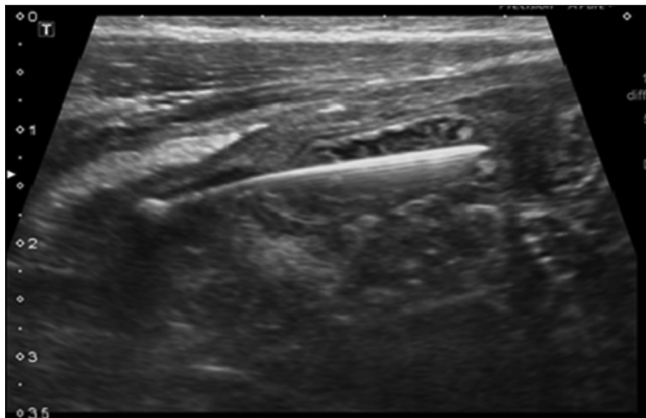

Figure 1: Sonographic imaging of right lower quadrant

Declaration of patient consent

The authors certify that they have obtained all appropriate patient consent forms. In the form, the legal guardian has given his consent for images and other clinical information to be reported in the journal. The guardian understands that names and initials will not be published and due efforts will be made to conceal patient identity, but anonymity cannot be guaranteed.

Financial support and sponsorship

Nil.

Conflicts of interest

There are no conflicts of interest.

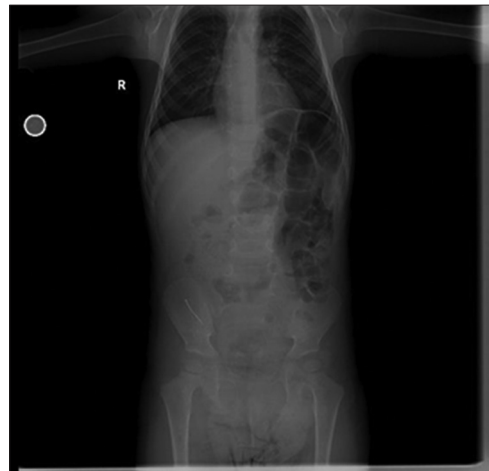


Figure 2: Abdominal radiography

Received: 13-02-2021 Revised: 08-05-2021 Accepted: 04-06-2021 Available Online: 29-07-2021

Access this article online

Quick Response Code:



Website:
www.jmuonline.org

DOI:
10.4103/JMU.JMU_40_21

Address for correspondence: Dr. Oğuzhan Tokur,
Department of Radiology, Ankara Training and Research Hospital,
Ankara, Turkey.
E-mail: oguzhantokur@gmail.com

This is an open access journal, and articles are distributed under the terms of the Creative Commons Attribution-NonCommercial-ShareAlike 4.0 License, which allows others to remix, tweak, and build upon the work non-commercially, as long as appropriate credit is given and the new creations are licensed under the identical terms.

For reprints contact: WKHLRPMedknow_reprints@wolterskluwer.com

How to cite this article: Üner Ç, Tokur O, Aydın S, Gökharman FD. A pediatric right lower quadrant pain case. *J Med Ultrasound* 2022;30:315.